

Phyllanthus amarus protects against potassium-dichromate pituitary toxicity via the oxidative pathway and improves the gonadotropins in male Wistar rats

Kingsley Afoke Iteire

Department of Anatomy, University of Medical Sciences, Ondo, Ondo state, Nigeria

 <https://orcid.org/0000-0002-5786-2926>

Charity Ayomide Adenodi

Department of Anatomy, University of Medical Sciences, Ondo, Ondo State, Nigeria

 —

Corresponding author: afokeone@gmail.com

Olalekan Marvelous Olatuyi

Department of Pharmacology, University of Medical Sciences, Ondo, Ondo State, Nigeria

 —

Raphael Eguono Uwejiho

Department of Anatomy, University of Medical Sciences, Ondo, Ondo State, Nigeria

 —

Temidayo Daniel Adeniyi

Department of Medical Laboratory Science, University of Medical Sciences, Ondo, Ondo State, Nigeria

 —

DOI: <https://doi.org/10.20883/medical.e834>

Keywords: Potassium Dichromate, *Phyllanthus amarus*, Oxidative Stress

Published: 2023-06-29

How to Cite: Iteire KA, Adenodi CA, Olatuyi OM, Uwejiho RE, Adeniyi TD. *Phyllanthus amarus* protects against potassium-dichromate pituitary toxicity via the oxidative pathway and improves the gonadotropins in male Wistar rats. Journal of Medical Science. 2023;92(2):e834. doi:10.20883/medical.e834



© 2023 by the author(s). This is an open access article distributed under the terms and conditions of the Creative Commons Attribution (CC BY-NC) license. Published by Poznan University of Medical Sciences

ABSTRACT

Background. *Phyllanthus amarus* is an antioxidant plant with numerous beneficial biological activities, but scarce information on its neuroprotective role against potassium dichromate (PDC)-induced neurotoxicity. This research investigated the antioxidant effect of aqueous *Phyllanthus amarus* leaf extract (APALE) on PDC-induced rats.

Materials and methods. Fifty male Wistar rats (120-130g) were randomized into five groups (A-E, n=10). Group A: (Control) distilled water; B: 300mg/kg APALE; C: 17mg/kg PDC; D: 17mg/kg PDC + 400mg/kg APALE; E: 17mg/kg PDC + 200mg/kg APALE. Administrations were once daily via an orogastric cannula for 28 consecutive days. At the end of the experiment, blood samples were obtained for hormonal assay (FSH and LH). The animals were euthanized, and pituitary glands were harvested and homogenized for Superoxide Dismutase (SOD) and Catalase (CAT), Glutathione Reductase (GSH) by x-ray crystallography, Malondialdehyde (MDA) by thiobarbituric acid reacting substances (TBARS) and paraffin embedding sections, for histological and histochemical evaluations.

Results. Morphometric analysis revealed that PDC caused a reduction in body and brain weights, volume, and weight of the pituitary gland. Masson trichrome demonstrates excessive accumulation of collagen fibers on PDC-treated tissues resolved by APALE. There was a significant increase in MDA in the PDC group and a decrease in the APALE groups compared to the control. In APALE groups, the SOD, CAT, GSH, and T-Protein levels significantly increased compared to the control group. PDC significantly decreased LH and FSH levels compared to the control. However, APALE restored these changes.

Conclusions. APALE demonstrated potent protective activity against PDC-induced pituitary toxicity.

Introduction

Neurotoxicity is the direct or indirect effect of chemicals that disrupt the nervous system of humans or animals [1]. It is a form of toxicity when a biological, chemical, or physical agent introduced into the body adversely affects the anatomy and physiology of the central and peripheral nervous systems. Neurotoxins are synthetic or natural substances that can damage or impair the nervous system's proper functioning. Neurotoxicity is caused by exposure to neurotoxins like chemotherapy drugs, radiation, heavy metals, industrial solvents, insecticides, and pesticides.

Potassium is a silvery white metal that reacts quickly with atmospheric oxygen and is found naturally in foods. It maintains the normal level of fluids in the body and conducts electrical impulses throughout the body. Overdose of potassium has been linked to fatigue, paralysis, nausea, vomiting, and diarrhea [2]. The potassium salt of dichromic acid (potassium Dichromate) is an inorganic chemical with oxidizing, allergen, and sensitizer attributes. Potassium dichromate is mainly used in producing potassium dichromate alum in the leather tanning industry. It is also used as a raw material for chromic acid and cement production [3]. It is chronically harmful to human health and the environment. It affects vision by causing blurred vision, redness, pain, and severe tissue burns. Severe exposure to potassium dichromate can result in blindness, ulceration, and skin ulceration. It has been demonstrated to induce toxicity associated with oxidative stress in animals and humans [4].

Phyllanthus amarus (Bhumya amalaka, *Phyllanthus amarus* Schumis) of the family of Euphorbiaceae, is an herbal leaf plant primarily found in tropical and subtropical regions of Americas, China, South East Asia and Africa. It contains dif-

ferent classes of organic compounds of medicinal importance, including alkaloids, flavonoids, hydrolyzable tannins (Ellagitannins), major lignans, polyphenols, triterpenes, sterols, and volatile oil. *Phyllanthus amarus* contains several pharmacologically important biomolecules whose efficacy has been well-established by several biochemical and pharmacological studies, [5, 6]. It is most commonly used in the Indian Ayurvedic system of medicine in conditions of the stomach, genitourinary system, liver, spleen, and kidney problems [7-9] also for a variety of ailments including dropsy, diabetes, jaundice, asthma and bronchial infections [10]. *Phyllanthus amarus* has been proven to have antioxidant properties and devoid of genotoxicity and pro-oxidant property [5, 8]. This study aims to elucidate the neuroprotective effect of *Phyllanthus amarus* on oxidative stress, hormonal imbalance, and histology of potassium dichromate induced-neurotoxicity in the pituitary gland of male Wistar rats

Materials and methods

Research design

Fifty adult male Wistar rats weighing an average of 120-130 g divided into five groups (n = 10), as shown in **Table 1**.

Extraction of Aqueous Extract of *Phyllanthus amarus*

Fresh leaves of *Phyllanthus amarus* were harvested in bulk from the environs of the University of Medical Sciences, Ondo, Ondo State. The leaves were immediately taken for identification at the Plant Biology Department, Adeyemi College of Education, with Batch Number CAE/BIO/22/010. The fresh leaves were air-dried for seven days, pulverized, weighed, and kept in an air-tight con-

Table 1. Treatment regimen across experimental groups.

Groups	Treatment
1 – Control	Received saline water
2 – APALE only	Received 300 mg/kg of aqueous <i>Phyllanthus amarus</i> leaf extract
3 – PDC only	Received 17 mg/kg of Potassium Dichromate
4 – High APALE + PDC	Received 400 mg/kg of aqueous <i>Phyllanthus amarus</i> leaf extract+ 17 mg/kg of Potassium Dichromate
5 – Low APALE + PDC	Received 200 mg/kg of aqueous <i>Phyllanthus amarus</i> leaf extract+ 17 mg/kg of Potassium Dichromate

tainer. Afterward, (600 g) was macerated in 6 liters of distilled water for 48 hours at 4°C in the refrigerator. The bottle with its container was sealed, kept at room temperature, and allowed to stand for seven days with irregular shaking. The extract was sieved, and the mixture was filtered on Whatman (No.1) filter paper. The filtrate was evaporated in an air-circulating oven at 42°C until dried. The crude extract was placed in small glass dishes and incubated at 28°C. Afterward, the extract was dissolved in an appropriate volume of distilled water to make different doses of 200 mg/kg, 300 mg/kg, and 400 mg/kg to be administered orally to experimental animals.

Chemicals and drugs

Normal saline; Potassium Dichromate (500 g; molecular weight 294.18; UN Number 3288) purchased from Pyrex Scientific Company, Benin; Donepezil from Uche Care Pharmacy LTD, Ondo.

Ethical approval and care of animals

The study was submitted for review, and approval was granted by the Research Ethical Committee of the University of Medical Sciences, with the ethical approval number NHREC/TR/UNIMED-HREC-Ondo St/22/06/21. The experiment was conducted at the Department of Anatomy, Faculty of Basic Medical Sciences, University of Medical Sciences. The animals were acquired from the Laboratory Animal Centre of the University of Medical Sciences, Ondo. They were fed with standard rodent pellet food and water ad libitum throughout the experimental period. They were acclimatized for one week before the commencement of the experiments, after that; each animal was randomly distributed according to the experimental design. Experimental animals used in this research were cared for and maintained in the animal facility regulations, guidelines, and policies governing the use of animal research as described in public health service policy on human care and use of laboratory animals, as approved by the Institute of Laboratory Animal Resource, National Research Council [11].

Determination of body weight, brain weight, and brain volume

The experimental animals were weighed weekly before the commencement of the experiment and during the experiment using an electronic

digital weighing scale (Ohaus). On completion of the experiment, the rats were sacrificed by cervical dislocation. The brains were dissected and weighed using a light-sensitive weighing balance. Brain volume was accessed by displacement of liquid.

Determination of Histological Demonstration

After 28 days of administration with a 24 (twenty-four) hours window of the last administration, the skulls were opened using bone forceps to expose the rat's brain, and the whole brain was fixed in 10% formal saline. The brain tissues were excised and dissected, and the pituitary glands were obtained stereotaxically. The pituitary gland was processed for paraffin embedding. Sections were stained for histological and histochemical evaluations using Hematoxylin and eosin and Masson trichrome staining techniques respectively.

Determination of hormonal level

Blood samples collected through the rats' retro-orbital vein for analysis of the Follicle Stimulating Hormone and Luteinizing hormones were centrifuged for 15 minutes using a centrifuge model 800B. The serum extracted was frozen until the time of the analysis. The hormones were analyzed through immunoassay method using a Microplate Reader model: MSLER08 manufactured by Medsinglong Global Group Co., Ltd, China.

Determination of concentration of biochemical activities

The homogenate of the pituitary glands was obtained and then centrifuged at 12,000 rpm to obtain the supernatant containing tissue lysates. The supernatants obtained were stored at low temperatures and assayed to analyze the concentration of Superoxide dismutase (SOD), catalase (CAT), Malondialdehyde (MDA), and Glutathione Reductase (GSH) activities in the tissue lysates using appropriate enzyme lysate immunosorbent assay kits.

Statistical analysis

Statistical analysis was performed using the GraphPad Prism statistical package (version 8).

Results generated from the studies were presented as Mean \pm S.E.M. One-way ANOVA and Two-way ANOVA were used to determine any significant difference among the groups with a confidence limit of 95% (0.05).

Results

Physical observations

The rats treated with PDC had a reduced feeding habit and an increased mortality rate. Some clinical signs observed include swollen testes, eye discharge, gum injuries, and cannibalism. Rats administered with only APALE for 28 days did not exhibit the above signs.

Effect of treatment on body weight, brain weight, pituitary gland weight, and brain volume

Fig. 1 shows a Morphometric analysis of body weight, pituitary gland weight, brain weight, and volume across all the experimental groups. A significant decrease ($p < 0.05$) was observed in the final body weight of rats treated with PDC only when compared to the control. Also, there was a significant ($p < 0.05$) increase in the final body weight of rats pretreated with 200 mg/kg, 300 mg/kg, and 400 mg/kg body weight of *Phyl-*

lanthus amarus when compared to the PDC-only group (chart A). Morphometric analysis of the brain weights revealed a substantial reduction in the brain weight of the PDC-only treated group compared to the control group (chart B). Brain volume showed no significant difference between the groups, although a slight reduction in brain volume was noticed in the PDC group compared to the control group (chart C). A significant difference was observed between the control and PDC-only-treated groups in pituitary gland weight. Results showed that PDC-treated rats substantially reduced the pituitary gland's weight compared with the control (chart D).

Effect of treatment on histology of pituitary gland

Hematoxylin and Eosin (H&E)

Fig. 2 shows the histology of the sections of the pituitary gland showing the distinct blue-stained nuclei of pituitary neurons in the groups (yellow arrows). In plates A and B (control & APALE groups), there is no distinct or observable alteration in tissue morphology compared to C (PDC group). Plate C (PDC group) shows several distorted neurons at different stages of degeneration, nuclear dissolution and fragmentation, and

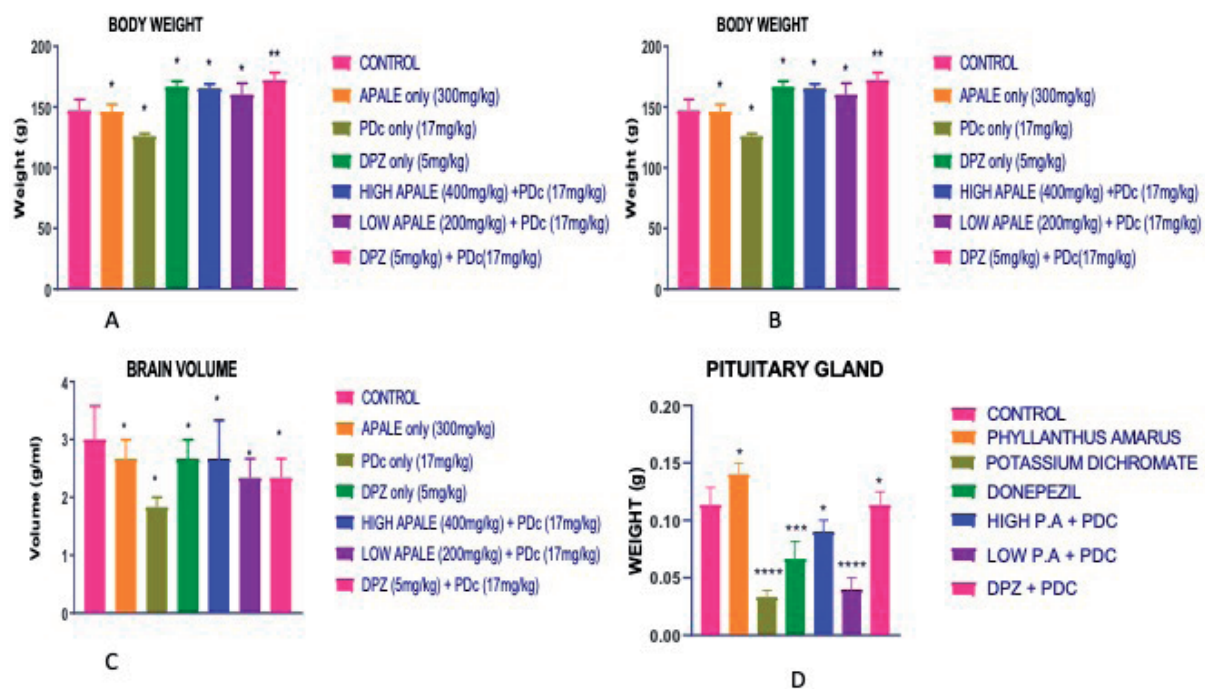


Figure 1. Morphometric analysis of body weight, pituitary gland weight, brain weight, and volume across all the experimental groups.

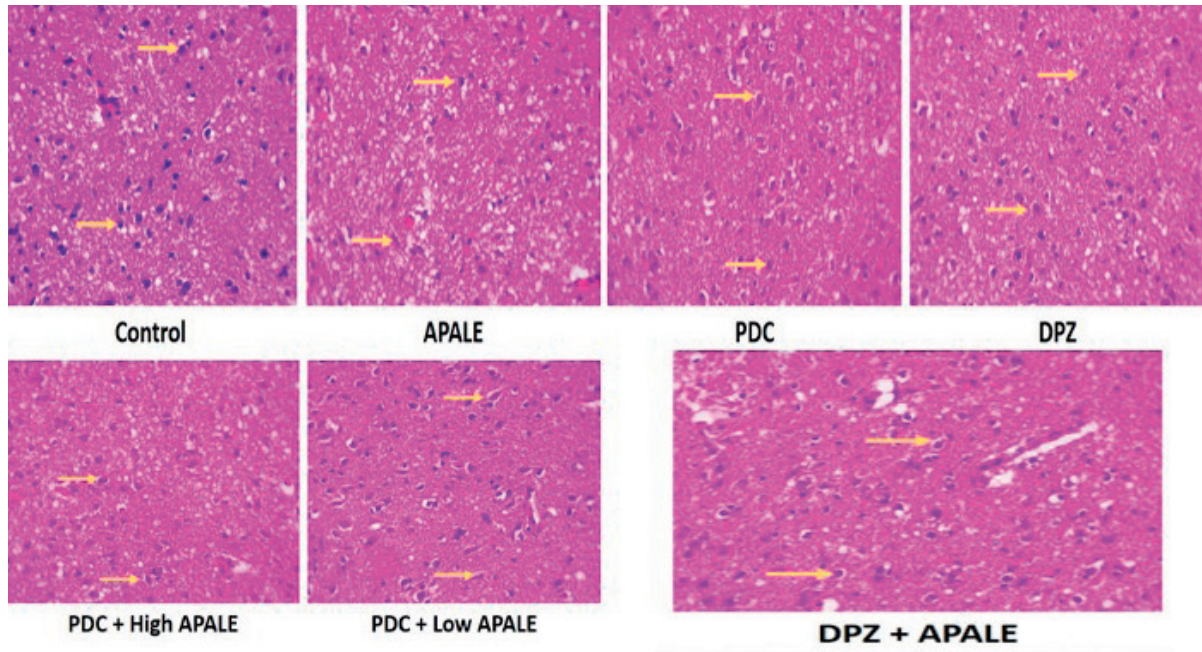


Figure 2. Histology of the sections of the pituitary gland showing the distinct blue-stained nuclei of pituitary neurons in the groups (yellow arrows).

vacuolation compared to the other groups. Plates D & E (low & high APALE groups) show signs of recovery compared to the control group.

Masson trichrome staining

Fig. 3 shows the histology of the sections of the pituitary gland tissue with red-stained distinct

neurons on a red background in all tissues. However, the administration of PDC (plate C) resulted in the accumulation of collagen fibers compared to the other groups (plate A, B, D, and E). the treatment with APALE at low and high doses significantly restored tissue appearance compared to control.

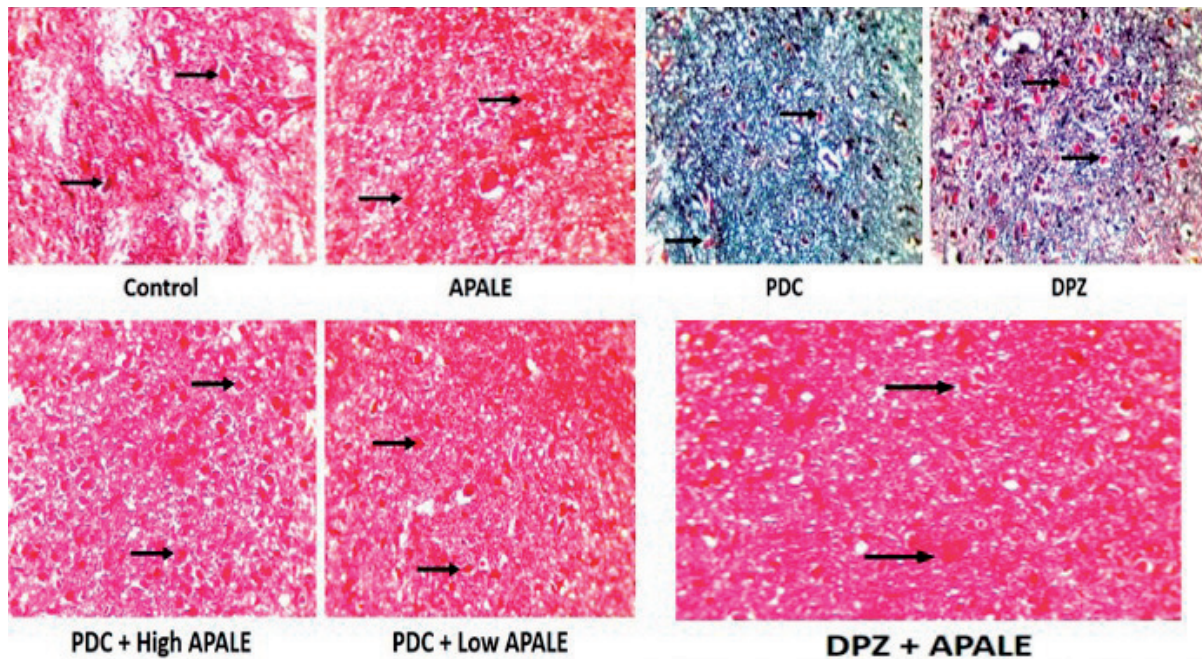


Figure 3. Histology of the sections of the pituitary gland tissue with red-stained distinct neurons on a red background.

Effect of treatment on the biochemical activity of the pituitary gland

Fig. 4 shows the charts for the oxidative stress markers. A significant increase ($p < 0.05$) was observed in the SOD level of rats treated with 200 mg/kg of APALE compared to the control and other groups. There was no significant difference in T-protein levels among all the groups (chart B). A significant increase ($p < 0.05$) was observed in Catalase-level rats treated with 200 and 400 mg/kg of APALE compared to the control and PDC groups (chart C). A significant increase ($p < 0.05$) was observed in the GR level of rats treated with 300 mg/kg of APALE compared to the control. No significant difference was observed in the

other treatment groups compared to the control group (chart D). A significant increase ($p < 0.05$) was observed in the MDA level of rats treated with PDC compared to the control, while a significant decrease ($p < 0.05$) in the level of MDA of rats treated with 200 mg/kg and 400 mg/kg of APALE compared to the PDC only group (chart E).

Effect of treatment on the hormonal level

Fig. 5 shows the charts for the hormonal assay. No significant difference was observed in the LH and FSH levels of rats treated with PDC compared to the control. However, there was a significant ($p < 0.05$) increase in the level of LH and FSH of rats treated with 200 mg/kg, 300 mg/kg, and

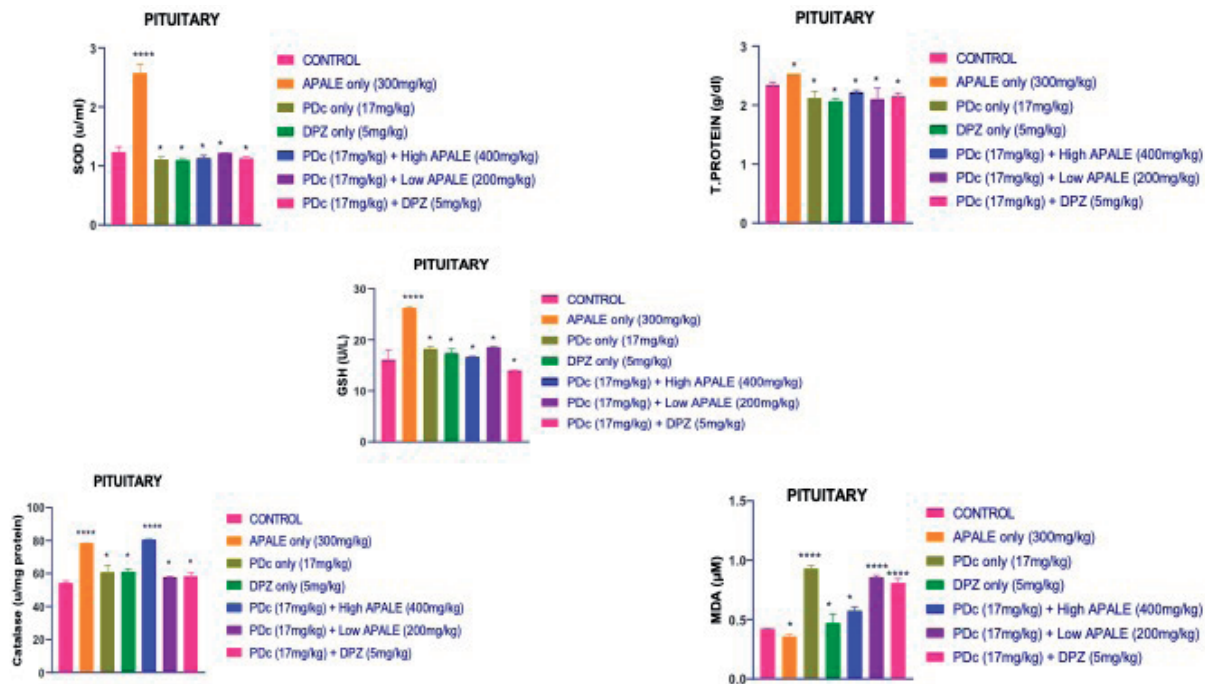


Figure 4. Charts for the oxidative stress markers.

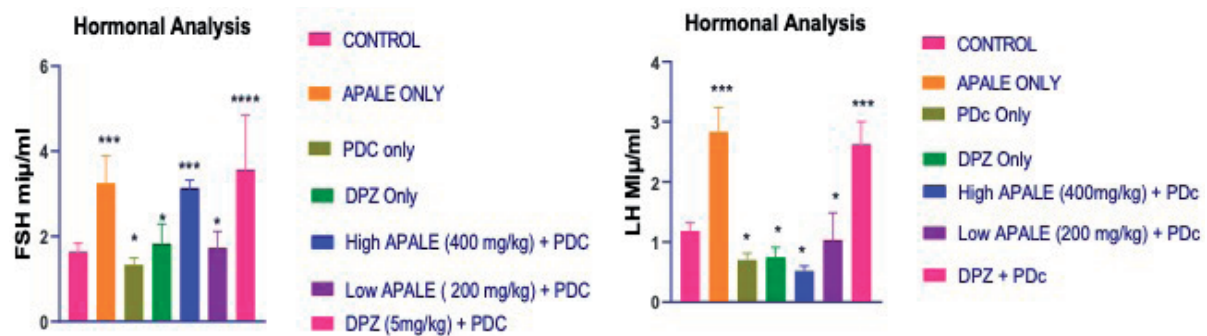


Figure 5. Charts for the hormonal assay.

400 mg/kg of *Phyllanthus amarus* when compared to the PDC-only group.

Discussion

This study sought to develop a novel natural-based neuroprotective agent against chromium-induced pituitary damage and consequent infertility following exposure to potassium dichromate. *Phyllanthus amarus* (APALE) was chosen for the study because of its protective properties [12-14]. In this study, the overall body weight of all experimental animals across the groups was measured and analyzed at the end of the administration period. It was noticed that oral administration of potassium dichromate to Wistar rats led to a significant decrease in body, brain, and pituitary weight. However, different treatments with APALE resulted in a significant weight gain in the body, brain, and pituitary gland. Weight loss is considered an indication of an underlying condition. Evidence indicates that metal toxicity in rats is associated with body and brain weight loss and morphological damage if not treated appropriately [15]. According to Momo [4], animals treated with potassium dichromate registered a significant decrease in body weight in a dose-dependent manner compared to animals that received only distilled water. In addition, Snejana and colleagues reported a significant decrease in daily feed consumption in animals exposed to potassium dichromate and, consequently, a reduction in body weight compared to animals treated with water [16], corroborating the findings of the above studies, our results elaborate on the body, brain, and pituitary weight loss due to reduced feeding in the rats exposed to PDC. Besides, it has been proven that the toxicity of heavy metals is a significant threat, and several health risks are associated with it; chronic exposure to heavy metals was associated with weight loss and brain damage [17]. Significantly, APALE proved its neuro-protective role against PDC-induced neurotoxicity by protecting against body, brain, and pituitary gland weight loss.

Collagen accumulation (fibrosis) was observed and stained with Masson trichrome in tissues of animals treated with oral administration of potassium dichromate. In addition, PDC caused nuclear distortion and fragmentation,

as shown in our H & E photomicrographs. However, different treatment doses of APALE resulted in significant restoration of the tissue appearances and distortion. Fibrosis is the formation of fibrous connective tissue in response to an injury. It is characterized by collagen accumulation at the injury site; continued activation is highly detrimental and a final pathway of numerous diseases [18]. Besides, Bucher [19] has observed focal ulceration, hyperplasia, and metaplasia in rats and mice consuming sodium dichromate-treated water. Furthermore, it has been previously reported in some studies that chromium accumulates in both the pituitary and hypothalamus, thereby resulting in apoptotic damage to neuronal nuclei (nuclear fragmentation) and caspase 3 upregulation [19, 20] this is consistent with our findings from this study.

The mechanism of PDC action is associated with mitochondrial and lysosomal injury by biologic chromium (VI) reactive intermediates and reactive oxygen species (ROS) [21]. Hence, biochemical activities were measured and analyzed at the end of the administration period by assaying the level of concentration of Superoxide Dismutase (SOD), Catalase (CAT), Glutathione Reductase (GSH), Total protein, and Malondialdehyde (MDA). Superoxide Dismutase (SOD) is an enzyme that constitutes a crucial antioxidant defense against oxidative stress. Its mechanism of action involves acting as a good therapeutic agent against reactive oxygen species-mediated diseases [22]. Our study observed that rats treated with APALE only had the highest level of SOD compared to the other groups pretreated with PDC before APALE.

In contrast, those treated with PDC only showed reduced levels of SOD compared to the control group. This finding was also evident in the report of Momo et al., which indicated that rats treated with PDC registered a significant decrease in the level of SOD [15]. In addition, Ogunmoyole and colleagues noted that treatment with APALE restored the activity of SOD to a level comparable with the negative control [23]. It was further noticed that APALE in the treatment group could not restore the significant decrease in T-protein observed in the rats treated with PDC compared to the control group.

Catalase is a crucial antioxidant enzyme that reduces oxidative stress by destroying cellular

hydrogen peroxide to produce water and oxygen [24]. Rats treated with PDC had significantly lower catalase levels than the other groups. However, treatment with various doses of APALE significantly increased the level of catalase in rats treated with PDC. This result contradicts that of Momo [4], who posited that PDC administration decreased catalase activity levels compared to control animals. However, our result agrees with that of Ogunmoyole and colleagues, stating that treatment with APALE restored catalase activity in serum and tissue homogenates [23]. Besides, an increase in catalase suggests a response toward increasing ROS generation [25], which is important in the oxidative pathway.

Glutathione Reductase maintains the supply of reduced glutathione [26]. Protecting cells from toxicity and oxidative damage and maintaining redox balance are critical [27]. It was observed that rats solely treated with APALE had the highest level of GSH, while those pretreated with PDC before APALE had reduced GR but were not significant compared to the control. This finding contrasts with that of Momo and his colleagues, which suggests that PDC patients significantly had decreased GSH (also known as GR) [4]. However, it partly corroborates that Ogunmoyole and colleagues observed that treatment with APALE markedly raised intracellular GSH (GR) concentration [23].

Malondialdehyde (MDA), a lipid peroxidation product, is a biomarker for oxidative stress. It was observed that PDC administration resulted in an increase in the levels of MDA in rats. At the same time, those treated with various doses of APALE had significantly reduced levels of MDA. Momo et al. stated that those treated with PDC registered an increased level of MDA relative to the control [4]. Also, it is reported that APALE restored antioxidant capacity by inhibiting lipid peroxidation [23]. Significantly treatment with APALE restored and increased superoxide dismutase, glutathione reductase, total protein, and catalase activities while reducing malondialdehyde.

The gonadotropic hormones consist of LH and FSH, secreted by the adenohypophysis and only essential for reproduction. They are called gonadotropin because they stimulate the gonads (the testes in males and ovaries in females) [28]. LH is answerable for gonadal release of sex steroids. In the testes, LH binds to receptors on Ley-

dig cells causing synthesis and secretion of testosterone. In the ovary, theca cells are activated in response to LH and secrete testosterone, this is converted to estrogen through the help of adjacent granulosa cells [28]. FSH is responsible for the stimulation and maturation of ovarian follicle in females and for sperm production in males. FSH supports Sertoli cells functions thereby aiding many facets of sperm cell maturation. The actuator of the secretion of gonadotropic hormone is GnRH, which is the chief controller of the HPG axis [28].

In this research, it was noticed that oral administration of potassium dichromate to Wistar rats led to a significant decrease in FSH and LH. However, different treatments with APALE resulted in a significant increase in FSH and LH levels. This protective effect could be occasioned by its antioxidant function, increasing the antioxidant protective mechanism of cells and tissues, thereby scavenging ROS and restraining lipid peroxidation of tissues. Evidence indicates that exposure to heavy metals like potassium dichromate adversely affects FSH and LH levels, including the hypothalamic-pituitary-gonadal axis, which plays a crucial role in the normal functioning of the reproductive system. According to Momo [4], animals treated with potassium dichromate registered abnormal levels of sex hormones. In addition, a significant decrease in levels of FSH and LH was recorded in potassium dichromate-treated as compared with control [4], corroborating the results of the above studies. The reduced secretion of LH could be an indication of increased Glucocorticoids secretion and decreased sensitivity of pituitary gonadotroph to GnRH, [29]. The gonads are directly affected by stress hormones which reduce the rate of Leydig cells response to LH or reduces testicular receptors to this hormone [29], with concurrent change in sex steroid production [30]. However, Glucocorticoids reduces sexual hormones receptors concentration by creating resistance in target tissues of gonadal steroids [29]. As a result, abatement in testosterone and reducing sexual incitement and fertility [30, 31].

It has been proven that PDC (VI) toxicity can be a potential risk to the reproductive system [32]. Significantly, APALE proved its neuroprotective role against PDC-induced neurotoxicity by protecting against the decreased level of FSH and LH.

Acknowledgements

The Authors wish to acknowledge the University of Medical Sciences, Ondo state, Nigeria.

Conflict of interest statement

The authors declare no conflict of interest.

Funding sources

There are no sources of funding to declare.

Authors' contributions

All authors contributed to the study conception and design. Material preparation, data collection and analysis were performed by all authors. The first draft of the manuscript was written by Iteire Afoke Kingsley Ph.D., and all authors commented on previous versions of the manuscript. All authors read and approved the final manuscript.

Availability of data and materials

All data are available on request from the corresponding Author.

References

1. Lein, P.J., Spencer, P.S. (2014). Neurotoxicity In: Wexler, P. (ed.), *Encyclopedia of Toxicology*, Elsevier Inc., Academic Press, 2014;3(3): 489–500. ISBN: 9780123864543
2. Oria, M., Harrison, M., & Stallings, V.A. Potassium: Dietary Reference Intakes for Toxicity – Dietary Reference Intakes for Toxicity – Dietary Reference Intakes for Sodium and Potassium – NCBI Bookshelf. 2019, March 5. <https://doi.org/10.17226/25353>. Accessed 20/12/2022.
3. Turito. Dichromate: Characteristics, Uses, Types. Retrieved December 23, 2022, from <https://www.turito.com/blog/chemistry/dichromate>
4. Mary Momo, C., Ferdinand N., Omer Bebe, N., Alexane Marquise, M., Augustave, K., Bertin Narcisse, V., Herve, T., et al. Oxidative Effects of Potassium Dichromate on Biochemical, Hematological Characteristics, and hormonal Levels in Rabbit Doe (*Oryctolagus cuniculus*). *Veterinary Sciences*. 2019; 6(1): 30.
5. Sonia Verma, Hitender Sharma, Munish Garg. *Phyllanthus Amarus: A Review*. *Journal of Pharmacognosy and Phytochemistry*. 2015; 3(2): 18-22
6. Surendra K. Sharma and M. A. Sheela. Pharmacognostic evaluation of leaves of certain *Phyllanthus* species used as a botanical source of *Bhumyamalaki* in Ayurveda. *Ayu*. 2011 Apr-Jun; 32(2): 250–253. doi: 10.4103/0974-8520.92552
7. Patel, R., Tripathi, P., Sharma, vikas, Chauhan, N. S., & Kumar, V. (2011, September 29). *Phyllanthus amarus*: Ethnomedicinal uses, phytochemistry, and pharmacology: A review. *J Ethnopharmacol*, 2011 Nov 18;138(2):286-313. doi: 10.1016/j.jep.2011.09.040. Epub 2011 Sep 29
8. Karuna, R., Reddy, S. S., Baskar, R., & Saralakumari, D. (2009, April). Antioxidant potential of aqueous extract of *Phyllanthus amarus* in rats. *Indian J Pharmacol*. 2009 Apr; 41(2): 64–67. doi: 10.4103/0253-7613.51342 PMID: PMC2841234
9. Jayaram, S., Thyagarajan, S.P., Sumathi, S., Manjula, S., Malathi, S., Madanagopalan, N., The efficiency of *Phyllanthus amarus* treatment in acute viral hepatitis A.B and non-A and non-B: an open clinical trial. *Indian Journal of Virology*, 1997; 13: 59–64.
10. Foo, L.Y., Wong, H., *Phyllanthusiin D* an unusual hydrolyzable tannin from *Phyllanthus amarus*. *Phytochemistry*, 1992; 31: 711–713.
11. National Research Council. *Guide for the Care and Use of Laboratory Animals*. 8th Edition. 2011;128-150. ISBN: 978-0-309-18663-6
12. Akilandeshwari Alagan, Ibrahim Jantan, Endang Kumolosasi, Satoshi Ogawa, Maizatun Atmadini A., Norazrina Azmi. Protective effects of *Phyllanthus amarus* against Lipopolysaccharide-induced neuroinflammation and cognitive impairment in rats. *Front Pharmacol*. 2019, 10: 632
13. B. Joseph and S.J. Raj, 2011. An overview: Pharmacognostic properties of *Phyllanthus amarus* Linn. *International Journal of Pharmacology*, 7:40-45
14. R. Karuna, Vijaya G. Bharathi, Sreenivasa S. Reddy, B. Ramesh, and D. Saralakumari. Protective effects of *Phyllanthus marus* aqueous extract against renal oxidative stress in streptozotocin- induced diabetic rats. *Indian J Pharmacol*. 2011; 43(4):414-418
15. Fiati Kenston, S. S., Su, H., Li, Z., Kong, L., Wang, Y., Song, X., Gu, Y., Barber, T., Aldinger, J., Hua, Q., Li, Z., Ding, M., Zhao, J., & Lin, X. (2018, January 29). The systemic toxicity of heavy metal mixtures in rats. *Toxicology Research* (RSC Publishing), 2018; 3: 311–540. <https://doi.org/10.1039/C7TX00260B>
16. Snejana Petrovici., Alexandra Trif., MilcaPetrovici., Eugenia Dumitrescu., Lucia Olariu., CameliaTulcan., and Alina Ghise. Effect of potassium dichromate intake on feed intake and body weight in female rats, *Rattus norvegicus* (exposure on three generations). *Human & Veterinary Medicine International Journal of the Bioflux Society*, 2010; 2(1), 31-35.
17. Jaishankar, M., Tseten, T., Anbalagan, N., Mathew, B. B., & Beeregowda, K. N. (2014, November 15). Toxicity, mechanism and health effects of some heavy metals – PMC. *PubMed Central* (PMC). 2014; 7(2): 60-72.
18. Murtha, L. A., Schuliga, M. J., Mabotuwana, N. S., Hardy, S. A., Waters, D. W., Burgess, J. K., Knight, D. A., & Boyle, A. J. (2017, September 22). The Processes and Mechanisms of Cardiac and Pulmonary Fibrosis. *Frontiers*. Retrieved February 21, 2023, from <https://www.frontiersin.org/articles/10.3389/fphys.2017.00777/full>
19. J. Bucher NTP toxicity studies of sodium dichromate dihydrate (CAS No. 7789-12-0) administered in drinking water to male and female F344/N rats and B6C3F1 mice and male BALB/c and am3-C57BL/6 mice *Toxic Rep Ser*, 2007;77: 1-G4
20. Silvana I. Nudler, Fernanda A. Quinteros, Eliana A. Miler, Jimena P. Cabilla, Sonia A. Ronchetti, Beatriz H. Duvilanski, Chromium VI administration induces oxidative stress in hypothalamus and anterior pituitary gland.

- itary gland from male rats, *Toxicology Letters*, 2009; 185(3): 187–192
21. A. Patlolla, C. Barnes, D. Hackett, P. Tchounwou Potassium dichromate induced cytotoxicity, genotoxicity and oxidative stress in human liver carcinoma (HepG2) cells *Int J Environ Res Public Health*, 2009; 6: 643–653.
 22. Younus H. (2018). Therapeutic potentials of superoxide dismutase. *International Journal of health sciences*. 2018; 12(3), 88–93.
 23. Ogunmoyole, Awodooju, Idowu, & Daramola. Phyllanthus amarus extract restored deranged biochemical parameters in rat model of hepatotoxicity and nephrotoxicity. *Phyllanthus Amarus Extract Restored Deranged Biochemical Parameters in Rat Model of Hepatotoxicity and Nephrotoxicity – ScienceDirect*, 2020; 6(12). <https://doi.org/10.1016/j.heliyon.2020.e05670>
 24. Ankita Nandi, Liang-Jun Yan, Chandan Kumar Jana, Nilanjana Das, "Role of Catalase in Oxidative Stress- and Age-Associated Degenerative Diseases," *Oxidative Medicine and Cellular Longevity*, Article ID 9613090, 2019; 2019:19. <https://doi.org/10.1155/2019/9613090>.
 25. K. Amin, S. Mohamed, T. El-Said, S. Khalid. The protective effects of cerium oxide nanoparticles against hepatic oxidative damage induced by monocrotaline *Int J Nanomed*. 2011;6: 143–149.
 26. Couto, N., Wood, J., & Barber, J. The role of glutathione reductase and related enzymes on cellular redox homeostasis network. *Free radical biology & medicine*, 95, 27–42. <https://doi.org/10.1016/j.freeradbiomed.2016.02.028>
 27. Forman, H. J., Zhang, H., & Rinna, A. Glutathione: overview of its protective roles, measurement, and biosynthesis. *Molecular aspects of medicine*. 2009; 30(1-2), 1–12. <https://doi.org/10.1016/j.mam.2008.08.006>
 28. VIVO pathophysiology, 2018. Available at <http://www.vivo.colostate.edu/hbooks/pathphys/endocrine/hypopit/lhfsh.html>. accessed 20/12/2022.
 29. Retana-Márquez, S., Juárez-Rojas, L., & Casillas, F. Interaction of Adrenal and Gonadal Axes during Stress in Males. *Research & Reviews: Journal of Zoological Sciences*. 2016; 4(1):13-17
 30. Hardy, M.P., Goa, H.B., Dong, Q., Ge, R., & Wang, Q. Stress hormone and male reproductive function. *Cell Tissue Respiration*. 2005; 322:147–153
 31. Retana-Márquez, S., & Biwer. Sexual behavior attenuates the effects of chronic stress in body weight, testes, sexual accessory glands, and plasma testosterone in male rats. *Hormones and Behaviour*. 2014; 66: 766–778.
 32. Banu, S. K., Samuel, J. B., Arosh, J. A., Burghardt, R. C., & Aruldhas, M. M. Lactational exposure to hexavalent chromium delays puberty by impairing ovarian development, steroidogenesis and pituitary hormone synthesis in developing Wistar rats. *Toxicology and applied pharmacology* 2008; 232(2), 180–189. <https://doi.org/10.1016/j.taap.2008.06.002>