



CASE STUDY

DOI: <https://doi.org/10.20883/medical.e77>

Ketoprofen, an emerging photoallergen

Ewelina Bogumiła Zuba¹, Agnieszka Osmola-Mańkowska², Dorota Jenerowicz², Maciej Stawny³, Magdalena Czarnecka-Operacz²

¹ Heliodor Świącicki University Hospital, Poznan University of Medical Sciences, Poland

² Department of Dermatology, Poznan University of Medical Sciences, Poland

³ Department of Pharmaceutical Chemistry, Poznan University of Medical Sciences, Poland

ABSTRACT

Introduction. Ketoprofen, which belongs to the group of non-steroidal anti-inflammatory drugs (NSAIDs), is an emerging photoallergen. Especially its topical use may be a cause of drug-induced photosensitivity.

Material and methods. We report two cases of photoallergic and one case of phototaggravated contact dermatitis due to topical ketoprofen application, confirmed by photopatch testing.

Results. All patients presented positive reactions to ketoprofen at an irradiated site. Only one patient demonstrated a positive reaction to ketoprofen both at an irradiated and non-irradiated site.

Conclusions. Photosensitive reactions due to topical application of ketoprofen being of significant clinical importance need to be properly diagnosed. It is crucial to provide patients with a detailed instruction how to protect photoexposed areas during therapy with ketoprofen.

Keywords: ketoprofen, photoallergic contact dermatitis, photoallergy, photosensitivity, photopatch testing.

Introduction

Ketoprofen belongs to the group of non-steroidal anti-inflammatory drugs (NSAIDs). It is widely used because of its well-known analgetic and anti-inflammatory properties. Photoallergic dermatitis is one of possible side effects of ketoprofen. In fact ketoprofen is considered to be one of the main photocontact allergens. The first case report of photoallergic reaction due to topical ketoprofen was published by a Spanish dermatologist in 1985 [1]. Since then, photoallergy to ketoprofen has been presented mostly by researchers originating from Mediterranean countries [2] as well as from Japan [3, 4], Belgium [5], Sweden [6] and recently also from Poland [7].

In this study, two cases of photoallergic contact dermatitis and one case of phototaggravated contact dermatitis due to topical use of ketoprofen have been presented.

Material and methods

Case 1

A 48-year-old female patient was directed to the Department of Dermatology, Poznan Medical University of Sciences in May 2011, with initially suspected erysipelas. The patient demonstrated itchy, erythematopapular skin lesions localized within the right calf and erythematous as well as exfoliating skin lesions within the left palm. There was neither fever nor malaise and new eczematous skin lesions on both lower extremities, neck and decollete appeared. Therefore diagnosis of erysipelas has been excluded. The patient reported on applying ketoprofen gel on her legs due to myalgia and previous exposure to the ultraviolet light while working in a garden during sunny weather, wearing short trousers. Our treatment was composed of clemastine 2 mg iv, dexamethasone 8 mg iv, 10 mg oral cetirizine, and topical betamethasone combined with gentamycin

in a cream formulation. Further on 1% hydrocortisone cream has been applied. Within the time period of nine days of the treatment significant improvement has been obtained.

Case 2

A 38-year-old female patient with a history of erythromelalgia related to idiopathic thrombocythemia, experienced erythematous and papular eruption on both lower legs, where she had previously applied ketoprofen gel to reduce burning pain associated with erythromelalgia. Further exacerbation of skin lesions has been reported by the patient after the sun exposure.

Case 3

A 22-year-old male developed itchy, erythematous and papular skin lesions with exudation, restricted to the site of application of ketoprofen. It has been prescribed by the general practitioner in order to reduce the contusion-related pain within the neck and left upper thorax. Highly itchy, erythematous and papular skin lesions with significant exudation, restricted to the site of the drug application appeared after 24 hours. A few hours after the first application of the medicine, the patient visited an outdoor swimming-pool.

Patch and photopatch testing

In case of all patients after remission of skin lesions diagnostic testing has been performed. The diagnostic

set consisted of standard patch tests (European Standard Patch Test Series, 28 haptens) provided by Chemotechnique Diagnostics. According to the International Contact Dermatitis Research Group recommendations evaluation of results has been performed after 48 and 72 hours.

Minimal erythematous dose (MED) was determined using mono-chromator irradiation simulator test and photopatch tests have been performed according to the European Guideline [8]. Medications tested included: diclofenac 1%, ibuprofen 5%, ketoprofen 2.5%, naproxen 5% (all in white petrolatum, which was also the negative control). Two photopatch series have been applied symmetrically on the back of patients for 48 hours, after which both were removed and one site has been irradiated with UVA at the dose of 5 J/cm². Test reactions have been evaluated 24 and 48 hours after irradiation. Results have been assessed according to the recommendations of International Contact Dermatitis Research Group.

Results

In case of all patients response to UV light was normal in MED testing. Patch tests' results with the European Standard Set of contact allergens were all negative. In all cases after 24 hours results of photopatch tests with ketoprofen were positive (erythema and papules). In cases one and two, positive reactions presen-

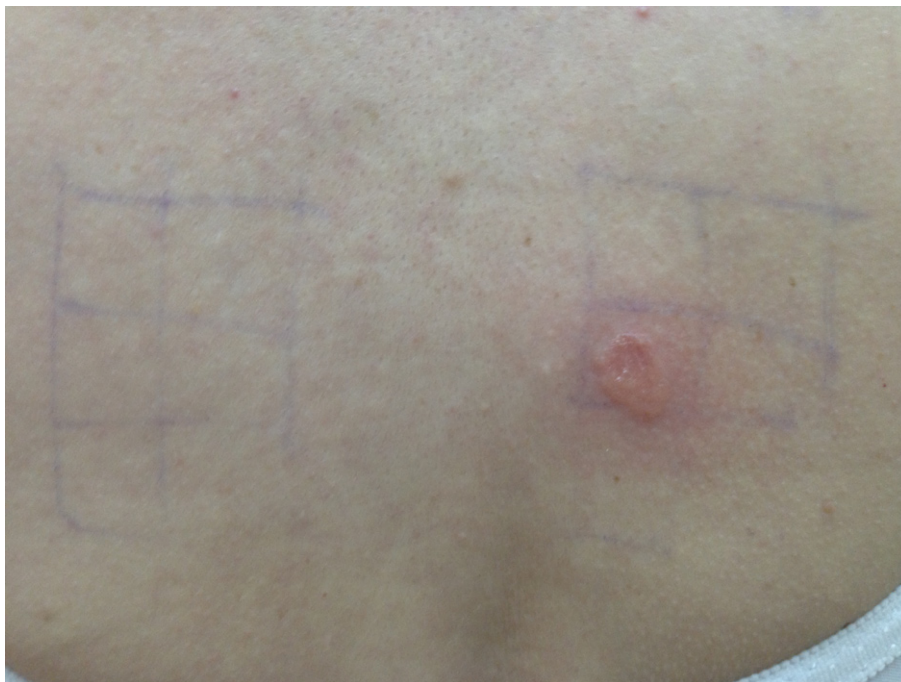

Figure 1. Photopatch testing of a 48-year-old woman

ted the 'crescendo' pattern with an increasing response (erythema, papules and vesicles) 48 hours after irradiation. Patch tests result with ketoprofen (at a non-irradiated site) was positive only in the case of patient three (++) in both readings. Based on results of our diagnostic procedure, patients one and two were diagnosed with photoallergic contact dermatitis and patient number three – as phototaggravated contact dermati-

tis. Results of photopatch testing have been presented in **Figures 1–3**.

Discussion

The two most common agent groups currently responsible for photoallergic contact dermatitis are organic ultraviolet absorbers in sunscreens and topical NSAIDs

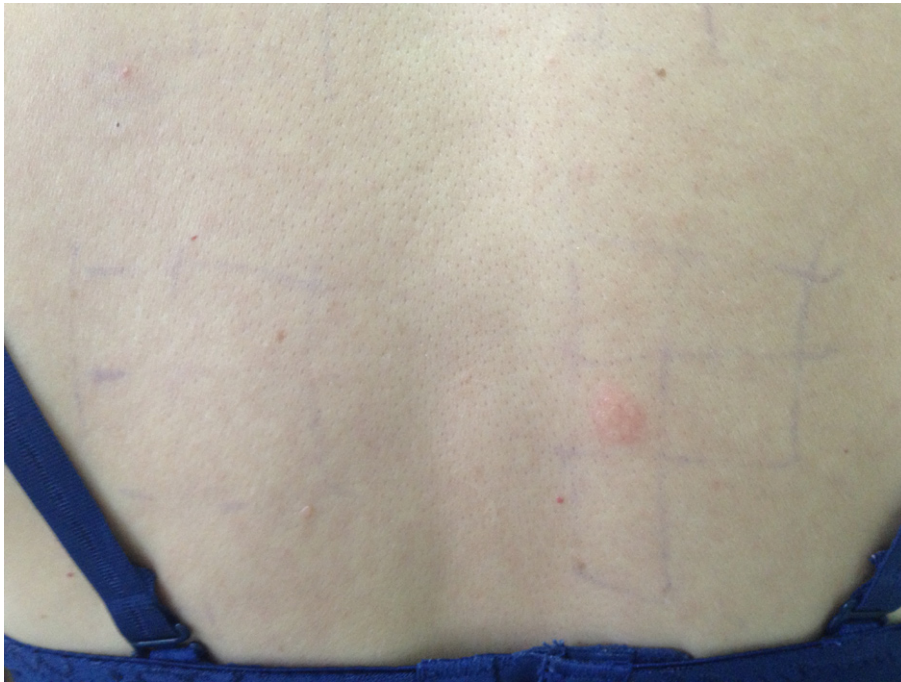


Figure 2. Photopatch testing of a 38-year-old woman

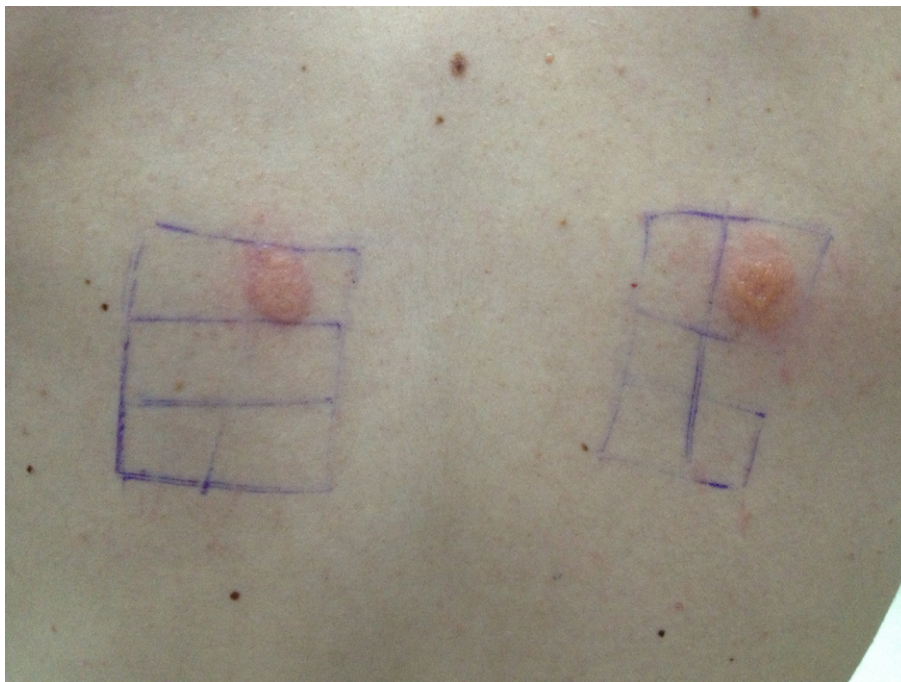


Figure 3. Photopatch testing of a 22-year-old man

[9, 10]. Ketoprofen is considered as the most common cause of NSAIDs-induced photosensitivity. It may promote phototoxic, photoallergic as well as phototaggravated reactions, where photoallergy is much more rare than phototoxic phenomenon [11]. Both topical and oral forms of ketoprofen are commonly prescribed by doctors of all professions.

Foti et al. [12], presented two cases of photodermatitis due to oral ketoprofen in patients with a history of photocontact reactions to topical ketoprofen. Both patients developed eczematous skin lesions after oral intake of ketoprofen and subsequent sun exposure. The authors highlight the risk of photoinduced reactions to systemic ketoprofen in patients with previous sensitisation to topical form of this drug.

Conti et al. [13] reported a case of a patient who developed acute eczematous reaction affecting the right lip commissure, and extending to the upper and lower lip and chin region after administration of oral granulated ketoprofen (OKI) and subsequent sun exposure. The patient never experienced any cutaneous reaction due to systemic ketoprofen, but only when the granules came in contact directly with the perioral skin followed by exposure to the sun. A positive reaction to only photostimulated ketoprofen was observed.

Recently published studies [14, 15] demonstrated that photoallergy to ketoprofen is often associated with photoallergy to octocrylene, and benzophenone-3, which are compounds of sunscreens. Therefore patients, who have experienced a photoallergic reaction to ketoprofen, should be informed about importance of avoiding sun blockers, which contain octocrylene and benzophenone-3.

Although photocross-reactivity to ketoprofen, octocrylene and benzophenone-3 is well-known, such a cross-reactivity between ketoprofen and butyl methoxydibenzoylmethane, a compound of sunscreen preparations, was not reported. Recent research [16] has demonstrated that the addition of a UVA absorber to topical ketoprofen formulations may be effective to reduce the ketoprofen photosensitivity. The authors presented that butyl methoxydibenzoylmethane has a strong potential to reduce ketoprofen photosensitivity. From the viewpoint of cross-reactivity, it is considered that butyl methoxydibenzoylmethane may be one of the best choices as a UVA filter added to topical ketoprofen formulations to prevent photosensitive reactions to ketoprofen.

According to recommendations of the European Medicines Agency's Committee for Medicinal Products for Human Use (CHMP) [17], ketoprofen is not availab-

le over the counter in Poland due to significant risk of severe photosensitivity reactions and cross allergy with octocrylene. Medical professionals should inform their patients about photosensitive reactions being a highly possible side effect of ketoprofen. Patients should also protect treated skin areas against UV during topical therapy with ketoprofen and two weeks after termination of the treatment.

On the basis of the results of the European Multi-centre Photopatch Test Study [9], and on the presence or absence of photosensitizing agents in consumer products within the European market, a recommended European Baseline photopatch test series has been changed. Ketoprofen, etofenamate, piroxicam, benzydamine, promethazine, and 15 compounds of sunscreens, including octocrylene, and benzophenone-3, are included in the new standard European Baseline photopatch test series [18].

Conclusion

Medical specialists should be aware, that avoiding prescriptions as well as selective use of topical ketoprofen formulations during sunny weather on photoexposed areas may contribute to the reduction of risk of severe photosensitive reactions or cross-sensitizations.

Conflict of interest

The authors declare no conflicts of interest concerning this article.

References

1. Alomar A. Ketoprofen photodermatitis. *Contact Dermatitis*. 1985 Feb;12(2):112–113.
2. Mozzanica N, Pigatto P. Contact and photocontact allergy to ketoprofen: clinical and experimental study. *Contact Dermatitis*. 1990 Nov;23(5):336–340.
3. Sugiura M, Hayakawa R, Kato Y, Sugiura K, Ueda H. 4 cases of photocontact dermatitis due to ketoprofen. *Contact Dermatitis*. 2000 Jul;43(1):16–19.
4. Sugiyama M, Nakada T, Hosaka H, Sueki H, Iijima M. Photocontact dermatitis to ketoprofen. *Am J Contact Dermatitis*. 2001 Sep;12(3):180–181.
5. Matthieu L, Meuleman L, Van Hecke E, Van Hecke E, Blondeel A, Dezfoulian B, et al. Contact and photocontact allergy to ketoprofen. The Belgian experience. *Contact Dermatitis*. 2004;50(4):238–241.
6. Hindsenn M, Zimerson E, Bruze M. Photoallergic contact dermatitis from ketoprofen in southern Sweden. *Contact Dermatitis*. 2006 Mar;54(3):150–157.
7. Jenerowicz D, Jakubowicz O, Polańska A, Sadowska-Przytocka A, Dańczak-Pazdrowska A, Żaba R. Photosensitivity to selected topical nonsteroidal anti-inflammatory drugs preparations – a review of literature data and author's

- own experience. *Centr Eur J Immunol.* 2001;36 (3): 197–203.
8. Bruynzeel DP, Ferguson F, Andersen KM, Gonçalo M, English J, Goossens A, et al. Photopatch testing: a consensus methodology for Europe. *J Eur Acad Dermatol Venereol.* 2004 Nov;18(6): 679–682.
 9. Kerr AC, Ferguson J, Haylett AK, Rhodes LE, Adamski H, Alomar A, et al. A European multicentre photopatch test study. *Br J Dermatol.* 2012 May;166(5):1002–1009.
 10. Chuah SY, Leow YH, Goon AT, Theng CT, Chong WS. Photopatch testing in Asians: a 5-year experience in Singapore. *Photodermatol Photoimmunol Photomed.* 2013 Jun; 29(3):116–120.
 11. De la Cuadra-Oyanguren J, Pérez-Ferriols A, Lecha-Carretero M, Gimenez-Arnau AM, Fernandez-Redondo V, Ortiz de Frutos FJ, et al. Results and Assessment of Photopatch Testing in Spain: Towards a New Standard Set of Photoallergens. *Actas Dermosifiliogr.* 2007 Mar;98(2):96–101.
 12. Foti C, Cassano N, Vena GA, Angelini G. Photodermatitis caused by oral ketoprofen: two case reports. *Contact Dermatitis.* 2011 Mar;64(3):181–183.
 13. Conti R, Bassi A, Difonzo EM, Moretti S, Francalanci S. A case of photoallergic contact dermatitis caused by unusual exposure to ketoprofen. *Dermatitis.* 2012 Nov-Dec;23(6):295–296.
 14. Avenel-Audran M, Dutartre H, Goossens An, Jeanmougin M, Comte Ch, Bernier C, et al. Octocrylene, an Emerging Photoallergen. *Arch Dermatol.* 2010 Jul;146(7):753–775.
 15. Devleeschouwer V, Roelandts R, Garmyn M, Goossens A. Allergic and photoallergic contact dermatitis from ketoprofen: results of (photo) patch testing and follow-up of 42 patients. *Contact Dermatitis.* 2008 Mar;58(3):159–166.
 16. Atarashi K, Takano M, Kato S, Kuma H, Nakanishi M, Tokura Y. Addition of UA-absorber butyl methoxydibenzoylmethane to topical ketoprofen formulation reduces ketoprofen-photoallergic reaction. *J Photochem Photobiol B.* 2012 Aug;113:56–62.
 17. European Medicines Agency confirms positive benefit-risk balance of topical formulations of ketoprofen. EA/CMP/465633/2010.
 18. Gonçalo M, Ferguson J, Bonevalle A, Bruynzeel DP, Giménez-Arnau A, Goossens A, et al. Photopatch testing: recommendations for a European photopatch test baseline series. *Contact Dermatitis.* 2013 Apr;68(4):239–243.

Correspondence address:

Ewelina Bogumiła Zuba
Heliodor Świącicki University Hospital
Poznan University of Medical Sciences
49 Przybyszewskiego Str., 60-355 Poznan, Poland
phone: +48 601158212
fax: +48 618691572
email: ewelina.zuba@interia.pl