




## CASE STUDY


DOI: <https://doi.org/10.20883/jms.278>


# Folliculitis decalvans – a case study and an overview of literature


Joanna Wróbel<sup>a</sup>, Anna Sadowska-Przytocka<sup>b</sup>, Dorota Jenerowicz<sup>c</sup>,  
Monika Bowszyc-Dmochowska<sup>d</sup>, Magdalena Czarnecka-Operacz<sup>e</sup>


Department of Dermatology, Poznan University of Medical Sciences, Poland

<sup>a</sup>  not available

<sup>b</sup>  not available

<sup>c</sup>  not available

<sup>d</sup>  not available

<sup>e</sup>  not available

### ABSTRACT

Folliculitis decalvans is a rare disease that leads to alopecia. This disease is a major challenge for physicians due to the therapeutic difficulties. This publication describes the case of a patient in whom a dermatological condition had improved after using doxycycline.

**Keywords:** folliculitis decalvans, alopecia, treatment.

## Introduction

Folliculitis decalvans is a rare disease belonging to the cicatricial alopecia group. It is a big challenge for a dermatologist to treat the disease because there are no clear guidelines concerning effective therapeutic methods. The disease was first described in 1888 by Quinquaud, who wrote that it was a chronic inflammation usually occurring in young adults of both sexes. In 1905 Brocq et al. named it folliculitis decalvans. The aetiopathogenesis of the disease has not been fully investigated. However, it seems that infection with *Staphylococcus aureus* (*S. aureus*) may play a significant role here with an inadequate immune response of the host [2, 4, 12]. Jahns et al. conducted immunofluorescence microscopy and fluorescent in situ hybridisation and proved that apart from *S. aureus*, other microorganisms were often responsible for folliculitis, e.g. *P. acnes* and coagulase-negative staphylococci [9]. There

are a few reports which suggest that head injury might result in predisposition for the disease [8].

Initially, the clinical image is predominated by erythematous papules and perifollicular pustules, which are usually covered by crust. The inflammation of follicles causes the emergence of alopecia foci with the characteristic 'brush symptom, i.e. tufts of residual hair. Progressing scarring alopecia is a characteristic feature of folliculitis decalvans. At the place where hair was lost the skin becomes atrophic and we can also observe erythema, follicular hyperkeratosis as well as erosions and hemorrhagic crusts. The usual locations are: top of the head and the occipital area, occasionally, the face (eyebrow and beard) and nape. Other extracranial locations are very rare. Patients complain about pain, the burning sensation and itchiness. Lesions may bleed periodically.

The disease is diagnosed on the basis of a typical clinical image and dermatoscopy. In

each case the diagnosis needs to be confirmed histologically. Early lesions are characterised by the accumulation of keratin in dilated follicular ostia, destruction of sebaceous glands as well as intra- and perifollicular neutrophilic infiltrates. When the disease is advanced, we can observe lymphocytes, numerous plasma cells and individual multinucleated giant cells. At the final stage of the disease fibrous strands replace hair follicles together with fibrosis in interfollicular skin.

They form overgrown scars, which are thicker and more cohesive than those observed in other diseases with initial perifollicular inflammations resulting in cicatricial alopecia [1, 2, 7, 8]. Differential diagnosis includes dissecting folliculitis of the scalp, acne keloidalis nuchae, erosive pustular dermatitis of the scalp, follicular lichen planus, kerion celsi as well as tufted folliculitis, which may be considered as a variant of folliculitis decalvans [7, 8].

## Case study

A 24-year-old female patient was admitted to the Dermatological Clinic to diagnose and treat lesions encompassing the hairy skin on her head and lower legs. The history of the disease spanned a period of few years. In 2008 the patient underwent septoplasty. A few days after the surgery first skin lesions appeared on her head and legs. About 4 years earlier the patient had had a traffic accident and suffered craniocerebral injury, which encompassed the frontoparietal region and the left craniofacial region. Due to the injury she had undergone an operation at the neurosurgical clinic.

Apart from that, the craniocerebral injury the patient suffered in 2004 resulted in blindness of her right eye, restriction of the visual field of her left eye, cerebral circulation disorder and disordered balance. The patient was a student of cosmetology and additionally worked as a cleaner. Her parents suffered from asthma and atopic dermatitis, whereas her sister did not tolerate gluten.

Patient presented with erythematous scaly areas localized on the extremities, with numerous pustules. It was diagnosed as superinfected eczema or folliculitis. Scalp lesions were initially diagnosed as seborrheic dermatitis. Later it was diagnosed as folliculitis decalvans accompanied

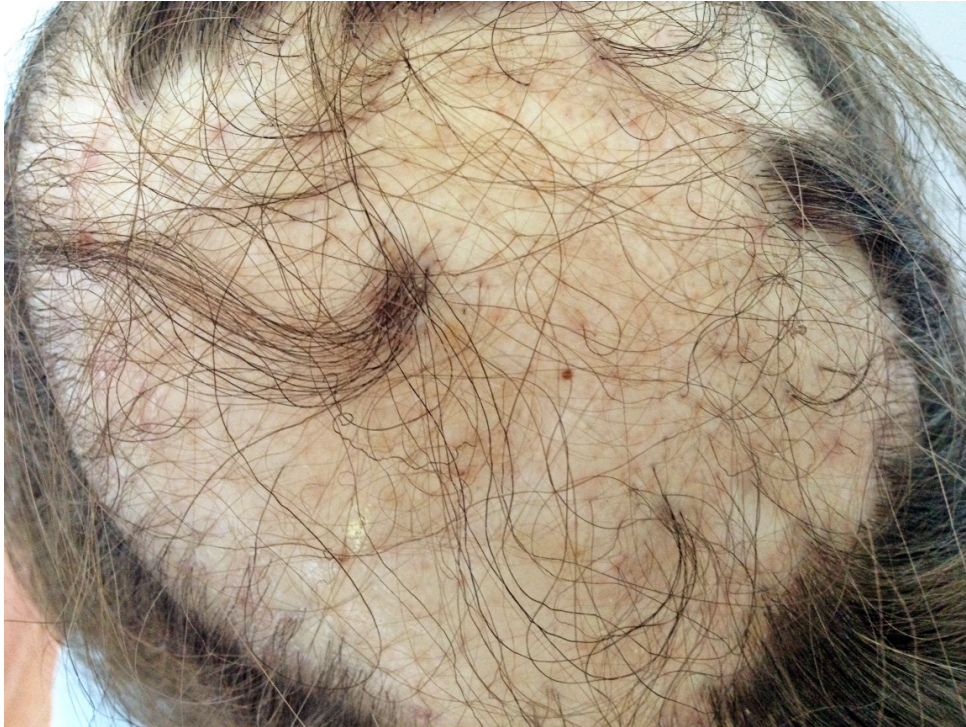by alopecia. Since the beginning of the disease the patient had been suffering from local itchiness.

Histopathological examination of the biopsy taken from the lesioned skin on the patient's right lower leg revealed *acanthotic epidermis with irregular rete ridges with intercellular oedema, infiltrated with neutrophils forming two micro-abscesses in the stratum corneum and moderate, mixed inflammatory infiltrates in the dermis – the image consistent with superinfected eczema*. The bacteriological test of the swab collected from a pustule in the lower leg region revealed infection with methicillin-sensitive *S. aureus* (MSSA), that confirmed the histopathological diagnosis.

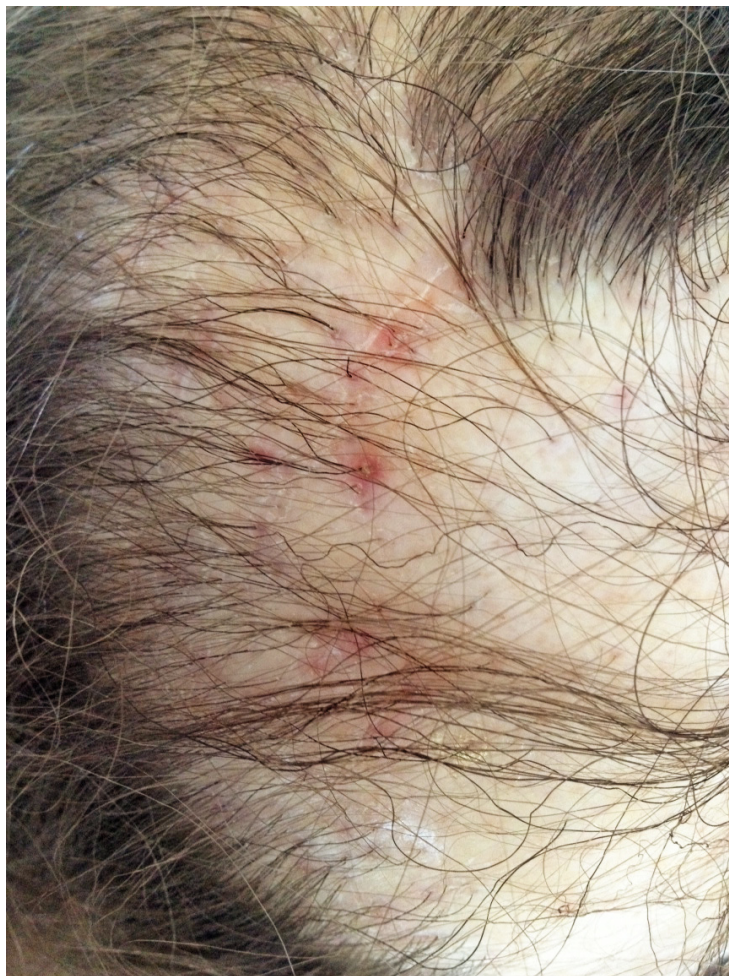Patient was treated with topical steroids and a combination of steroids and antibiotic. A steroid therapy lasting a few days had been included in systemic treatment twice. The patient had received antifungal drugs (itraconazole, probably) as well as antihistamine preparations and she had undergone an antibiotic therapy with doxycycline according to the antibiogram obtained in the microbial test of the swab collected from lesions in her lower legs. On the examination alopecia with tufts of residual hair located in the parietal region was observed (**Figure 1**). In the vicinity papules and perifollicular pustules predominated (**Figure 2**). Occasionally, individual erosions and crust could be found. There was a vast inflammatory infiltration. In the parietal region there were predominant traits of excessive keratosis with stratified scales. Apart from that, the image of the patient's lower legs was similar to that of folliculitis. The dermatological state deteriorated immediately before and during menstruation. The patient's lower legs were swollen then. The exacerbation was accompanied by pain and itchiness in the lesions.

Laboratory investigations conducted during the patient's hospitalisation revealed slightly reduced amounts of haemoglobin (up to 10.7 g/dl) and haematocrit (up to 31.5%), the limit content of erythrocytes ( $3.54 \times 10^6/\mu\text{l}$ ) and potassium (5.11 mmol/l) and a slightly reduced amount of urea (14 mg/dl). The anti-streptolysin O value was 250 IU/ml. Other markers of inflammation as well as the content of thyroid hormones and anti-thyroid antibodies remained normal.

A punch biopsy was taken from the lesional skin of the patient's head. The histopathological examination revealed: Disrupted hair follicles and fragments of hair shafts surrounded with mixed



**Figure 1.** Alopecia with tufts of residual hair located in the parietal region

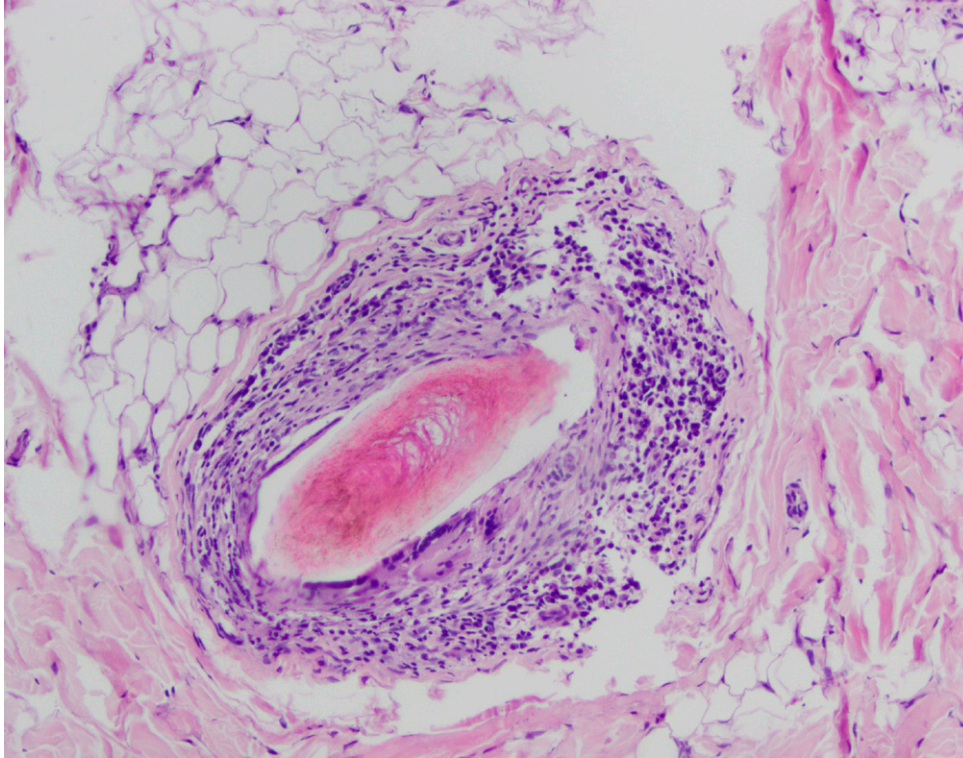


**Figure 2.** Papules and perifollicular pustules

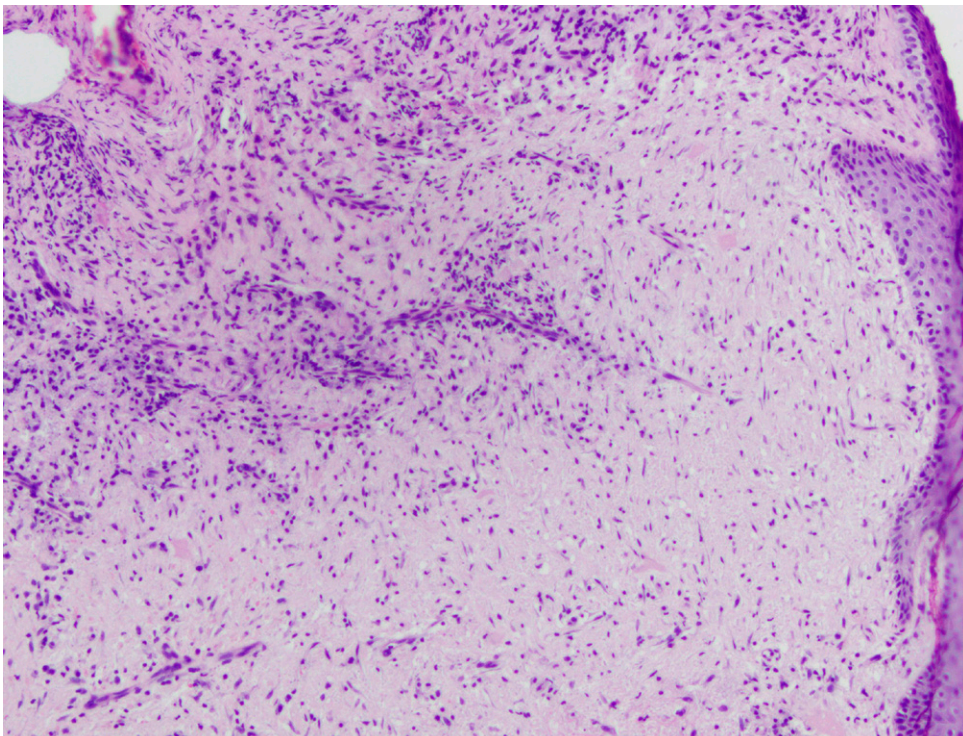
inflammatory infiltrates composed of giant cells, lymphocytes, histiocytes, plasmocytes and neutrophils (**Figure 3**). Epidermis was normal but the upper dermis between hair follicles was also infil-

trated with inflammatory cells and fibroblasts, the features of folliculitis decalvans (**Figure 4**).

The direct immunopathological examination of the skin specimen did not reveal IgA, IgM, IgG



**Figure 3.** Remnants of disrupted hair follicle surrounded with inflammatory infiltrate with giant cells and plasmocytes



**Figure 4.** Mixed inflammatory infiltrate and fibroblasts in the upper interfollicular dermis

or C3 deposits. The indirect immunofluorescence test revealed the presence of antinuclear antibodies (ANA) with a titre of 1/320, characterised by granular fluorescence. Laryngological consultation resulted in diagnosing chronic tonsillitis and nasal septum deviation. Bilateral tonsillectomy was recommended in the case of dermatological indications. The dentist did not find potential pockets of infection. The mycological culture was negative.

During hospitalisation (6 days) the patient received doxycycline administered intravenously at a dose of 2 x 100 mg, fluconazole administered orally at a dose of 1 x 50 mg and cetirizine at a dose of 2 x 10 mg. Twice a day fluocinolone acetonide gel was applied locally to the skin on the patient's head. 5% salicylic oil was recommended to be applied twice a day in the occipital region with predominant exfoliation and stratified crusts. Boric cream with 1% hydrocortisone was applied to the patient's lower legs twice a day. Boric cream was also recommended for the patient's arms and torso.

According to the information in the discharge summary, the therapy should be continued in an outpatient setting by applying doxycycline orally at the same dose for few weeks. A preparation with urea was recommended to be applied once a day locally in the occipital region. A regenerative preparation was recommended to be applied to other lesions on the patient's head. Preparations with 15% urea were recommended to be applied to the patient's lower legs.

## Discussion

The aetiopathogenesis of folliculitis decalvans has not been explained. It may be a problem to treat the disease.

Vano-Galvan et al. conducted a multi-centre study on 82 patients with symptoms of folliculitis decalvans. Hypotension, dyslipidaemia and thyroiditis were listed as concomitant diseases. Some patients also suffered from atopic dermatitis and hidradenitis suppurativa. None of the patients associated the occurrence of first skin lesions with any drug they received. However, the report described two cases of patients treated with erlotinib due to lung cancer and one case of a patient receiving lapatinib due to breast cancer. The average age of patients with the disease was

35 years. On average the diseases lasted about 4.6 years. There were three cases of positive family history with folliculitis decalvans (there were three male patients whose brothers suffered from the disease). There were two patients in the group who reported an earlier injury in the lesioned region. The researchers specified the scale of intensity of skin lesions, where foci smaller than 2 cm were classified as the first degree, foci ranging between 2 cm and 4.99 cm – as the second degree, whereas efflorescence of 5 cm or larger was classified as the third degree. The degree of classification depended on the maximum size of the largest focus of alopecia. Three groups with a benign (first degree), moderate (second degree) and acute (third degree) course of folliculitis decalvans were identified. There were respectively 40%, 39% and 21% of the patient population in each group. It seems that an early onset of dermatosis, i.e. before the age of 25, and the presence of pustules in alopecia foci prognose the acute course of the disease (third degree). The 'brush symptom' was usually described in the clinical image. Most of the patients had skin itchiness, pustules and scabs. More than a half of the patients had lesions on the top of their heads. Some of the patients had lesions in the parietal, occipital or frontal region. It was rarely found on their eyebrows or chin. In all the cases the diagnoses were confirmed by the histological examination, which showed cicatricial alopecia and different degrees of intra- or perifollicular inflammation and fibrous strands. In most of the patients microbiological tests revealed the presence of *S. aureus* in the swabs collected from pustules. The growth of *S. aureus* in the tested material was observed in all the patients whose nasal swabs were collected and analysed bacteriologically. The research did not confirm any correlation between the intensity of the disease and the patients' sex or location of efflorescence. There was no statistically significant correlation between the patients' sex, age, location of lesions and their response to treatment [4].

Questions about effective therapy cannot be omitted in the discussion on folliculitis decalvans. According to Powell et al., when rifampicin was administered orally twice a day at a dose of 300 mg in combination with clindamycin administered twice a day at a dose of 300 mg for 10 weeks, the patients' health improved. In most of

them pain was gradually relieved, the emergence of new pustules was inhibited and it was possible to control the inflammation. A few patients needed to have the ten-week therapy repeated two or three times. The research also proved that if there were contraindications against clindamycin, it was possible to apply combination therapy, where rifampicin was administered together with doxycycline, ciprofloxacin or clarithromycin. Powell et al. stressed the fact that rifampicin should not be used in monotherapy due to the high risk of drug resistance [2, 3]. Vano-Galvan et al. confirmed good response to treatment with rifampicin and clindamycin, but the remission observed in their research was shorter than in the aforementioned studies. The researchers noted the fact that apart from the strong bactericidal effect on *S. aureus*, rifampicin modified the cellular response of the organism by inhibiting the transformation of T lymphocytes. Vano-Galvan et al. suggested that alternatively doxycycline should be administered orally at a dose of 100 mg a day for 3–6 months, minocycline – at a dose of 100 mg a day for 3–6 months or if the patient exhibited intolerance to these drugs, azithromycin should be administered at a dose of 500 mg three times a week for 3 months. The authors indicated that this therapy reduced the risk of adverse reactions [4].

When corticosteroids were systemically applied, they did not have long-lasting effects although they blocked the inflammatory reaction. They should be taken into consideration as a short-term therapy if there is high intensity of the disease [4].

According to Otberg et al., the disease could be significantly inhibited by eradicating *S. aureus*. The authors recommended a wide range of orally administered antibiotics, such as: doxycycline, erythromycin, minocycline, co-trimoxazole, cloxacillin, sulfamethoxazole – trimethoprim, vancomycin, rifampicin and clindamycin as well as locally administered drugs, such as: fusidic acid, 2% mupirocin, 1% clindamycin and 2% erythromycin. However, it is necessary to remember that local antibiotic therapy is effective if there are very discreet lesions [5].

Steroids applied locally or administered by injection in the region of skin lesions help to reduce inflammation and the resulting itchiness, burning sensation and pain. They should supplement the antibiotic therapy [4, 5].

As far as isotretinoin is concerned, its application is limited due to the risk of adverse reactions and exacerbation of the disease, as was described in a few cases [4]. Gemmeke et al. applied a combination therapy with isotretinoin administered at a dose of 40 mg a day, clindamycin administered at a dose of 300 mg a day for 6 weeks and prednisolone administered at a dose of 20 mg a day for 3 weeks. The therapy was applied to a young patient and produced a good effect and remission during the six months of observation [11]. There are few reports on the application of dapsone. The dermatological state may be improved when the drug is applied at a dose of 50–100 mg daily, but when the therapy is finished, there is usually a relapse [5].

Bastida et al. described four cases where tacrolimus was locally applied in ointment and produced very good effects as inflammatory lesions remitted. When the immunomodulating drug is applied to lesioned skin, it inhibits signal transduction cascade in T lymphocytes. As a result, it prevents the synthesis of selected proinflammatory cytokines and blocks the release of inflammation mediators from mast cells, eosinophils and basophils. Apart from that, according to Bastida et al., tacrolimus increases the keratinocytes capacity to eliminate *S. aureus* by stimulating the expression of antibacterial proteins. However, when the therapy is stopped, the ailments usually remit. Bastida et al. stress the fact that the therapy they suggest does not eradicate *S. aureus*, so simultaneous antibiotic therapy might be helpful [6].

In case of resistance to the aforementioned treatment other methods can be applied, such as: Nd-YAG laser epilation, oral application of L-tyrosine and hydroxychloroquine, surgical treatment, photodynamic therapy or, as results from latest reports, adalimumab and infliximab [4, 5, 10, 11, 13].

Surgical reduction of lesions with hair transplantation can only be taken into consideration if there is a long-term remission after the therapy [5]. Miguel-Gomez et al. confirmed the efficacy of photodynamic therapy. The method consists in applying methyl aminolevulinate cream until occlusion and, after about 3 hours lesioned skin is exposed to radiation at a wavelength of 630 nm and dose of 37 J/cm<sup>2</sup> for 16 weeks. The photodynamic therapy improved the health of 90% of the patients under study. However, some patients

needed to have another method applied to sustain the effect. Due to the low comfort and uncertain effect of the method photodynamic therapy is reserved for the cases where pharmacotherapy is ineffective [10, 13].

Folliculitis decalvans is a chronic disease, where treatment includes limiting the inflammation and inhibiting alopecia. Hair regrowth should not be expected. The disease may relapse if the therapy is stopped. Therefore, it is important not only to select an adequate method of treatment for each patient with folliculitis decalvans but also to provide intensive psychological care.

### Acknowledgements

#### Conflict of interest statement

The authors declare no conflict of interest.

#### Funding sources

There are no sources of funding to declare.

### References

1. Braun-Falco O, Burgdorf WHC, Plewig G, Wolff HH, Landthaler. *Dermatologia*. Wydanie II polskie. Wyd. Czelej 2010. Rozdział 69. Choroby włosów.
2. Powell JJ, Dawber RP, Gatter K. Folliculitis decalvans including tufted folliculitis: clinical, histological and therapeutic findings. *Br J Dermatol*. 1999;140(2):328–33.
3. Brooke RC, Griffiths CE. Folliculitis decalvans. *Clin Exp Dermatol*. 2001;26(1):120–2.
4. Vano-Galvan S, Molina-Ruiz AM, Fernandez-Crehuet P, Rodrigues-Barata AR, Arias-Santiago S, Serrano-Falcon C et al. Folliculitis decalvans: a multicenter review of 82 patients. *J Eur Acad Dermatol Venereol*. 2015;29(9):1750–7.
5. Otberg N, Kang H, Alzolibani AA, Shapiro J. Folliculitis decalvans. *Dermatol Ther*. 2008;21(4):238–44.
6. Bastida J, Valeron-Almazan P, Santana-Molina N, Medina-Gil C, Carretero-Hernandez G. Treatment of folliculitis decalvans with tacrolimus ointment. *Int J Dermatol*. 2012;51(2):216–20.
7. James C, Langlois NE. Folliculitis decalvans: a rare scarring alopecia misinterpreted as laceration of the scalp at the scene. *Forensic Sci Med Pathol*. 2013;9(4):594–5.
8. Annessi G. Tufted folliculitis of the scalp: a distinctive clinicohistological variant of folliculitis decalvans. *Br J Dermatol*. 1998;138(5):799–805.
9. Jahns AC, Lundskog B, Nosek D, Killasil H, Emtestam L, Alexeyev OA. Microbiology of folliculitis decalvans: a histological study of 37 patients. *J Eur Acad Dermatol Venereol*. 2015;29(5):1025–6.
10. Miguel-Gomez L, Vano-Galvan S, Perez-Garcia B, Carrillo-Gijon R, Jaen-Olasolo P. Treatment of folliculitis decalvans with photodynamic therapy: Results in 10 patients. *J Am Acad Dermatol*. 2015;72(6):1085–7.
11. Gemmeke A, Wollina U. Folliculitis decalvans of the scalp: Response to triple therapy with isotretinoin, clindamycin and prednisolone. *Acta Dermatovenereol Alp Pannonica Adriat*. 2006;15(4):184–6.
12. Sri Venkateswaran K, Garg BR, Ratnakar C. Folliculitis decalvans. *Indian J Dermatol Venereol Leprol*. 1995;61(4):233–4.
13. Collier NJ, Allan D, Diaz Pesantes F, Sheridan L, Allan E. Systemic photodynamic therapy in folliculitis decalvans. *Clin Exp Dermatol*. 2018;43(1):46–9.

Acceptance for editing: 2018-06-30  
Acceptance for publication: 2018-07-02

#### Correspondence address:

Joanna Wróbel  
Department of Dermatology  
Poznan University of Medical Sciences, Poland  
email: joasiaurbanska@interia.pl